

An interesting case of fever, rash, and polyarthrititis

Uddalak Chakraborty, Tarun Kumar Paria,
Atanu Chandra, Jyotirmoy Pal

ABSTRACT

Introduction: Poncet's disease is a parainfective reactive arthritis seen with active tuberculosis (TB) where no mycobacteria can be demonstrated in the affected joints. This rare entity has been reported mainly with extrapulmonary TB, but very rarely associated with pulmonary TB and still remains a diagnosis of exclusion. **Case Report:** We report a case of a 15-year-old boy who presented to us on June 2018 with low grade fever, cough with mucoid expectoration, and bilateral symmetrical nonerosive polyarthrititis along with palpable purpura of both lower limbs and buttocks. On extensive investigations, he was diagnosed with secondary pulmonary TB on the basis of sputum examination (cartridge-based nuclei acid amplification test, CBNAAT) and radiological findings. Ultrasonography of the affected joints showed synovial thickening with minimal effusion in right knee joint, whereas joint fluid CBNAAT was negative ruling out intra-articular TB. Investigations were extensively carried out to rule out other autoimmune/infectious cause of the polyarthrititis and rash, which was finally attributed to Poncet's disease.

Skin biopsy revealed perivascular infiltration of fragmented neutrophils and lymphocytes, suggestive of leukocytoclastic vasculitis, supported by direct immunofluorescence test in favor of immunoglobulin A (IgA) vasculitis/Henoch–Schönlein purpura (HSP). The rash resolved simultaneously while the polyarthrititis improved markedly with anti-tubercular therapy. Hence a rare association of Poncet's disease with pulmonary TB and IgA vasculitis/HSP was made in this case. **Conclusion:** Tuberculosis may have protean manifestations even rash and arthritis, hence a clinician must be vigilant while dealing with such a constellation of symptoms.

Keywords: Pulmonary tuberculosis, Poncet's disease

How to cite this article

Chakraborty U, Paria TK, Chandra A, Pal J. An interesting case of fever, rash, and polyarthrititis. J Case Rep Images Med 2019;5:100053Z09UC2019.

Article ID: 100053Z09UC2019

doi: 10.5348/100053Z09UC2019CR

Uddalak Chakraborty¹, Tarun Kumar Paria², Atanu Chandra³, Jyotirmoy Pal⁴

Affiliations: ¹Postgraduate Trainee (PGY3), Department of General Medicine, R.G. Kar Medical College and Hospital, Kolkata, West Bengal, India; ²Postgraduate Trainee (PGY2), Department of General Medicine, R.G. Kar Medical College and Hospital, Kolkata, West Bengal, India; ³Assistant Professor, Department of General Medicine, R.G. Kar Medical College and Hospital, Kolkata, West Bengal, India; ⁴Professor, Department of General Medicine, R.G. Kar Medical College and Hospital, Kolkata, West Bengal, India.

Corresponding Author: Dr. Uddalak Chakraborty, 158, Chakdah Padma Pukur, Purba Putiary, Kolkata 700093, West Bengal, India; Email: uddaalakchakraborty@gmail.com

Received: 24 July 2019

Accepted: 22 August 2019

Published: 10 September 2019

INTRODUCTION

Fever with polyarthrititis and rash encompasses a large number of differentials which may include infectious causes, e.g., dengue, chikungunya, viral hepatitis, TB, etc., and autoimmune conditions, e.g., systemic lupus erythematosus, rheumatoid arthritis, Still's disease, etc., along with malignancies (predominantly hematological) and drug reactions/serum sickness [1]. Poncet's disease comprises of polyarthrititis probably due to tubercular rheumatism where no mycobacterial involvement can be demonstrated in the joints [2]. It usually presents

with a nondestructive symmetric polyarthritis and some school of thought suggests the entity as a parainfective reactive arthritis. The diagnosis is challenging and Poncet's disease is essentially a diagnosis of exclusion. A high index of suspicion may be required to identify this rare complication and early initiation of treatment is essential, as it responds dramatically to anti-tubercular therapy [3]. The pathogenesis of Poncet's disease is yet to be fully understood. It has been proposed that a vigorous immune response to mycobacteria occurs within the joints, followed by activation of T cells that leads to cross-reactivity between mycobacterial antigens with cartilage proteoglycans. Molecular mimicry between mycobacterial heat shock proteins and human heat shock proteins have also been suggested [4]. Poncet's disease has been reported with extrapulmonary TB, but very rarely associated with pulmonary TB.

CASE REPORT

A 15-year-old boy was suffering from a low grade fever with evening rise of temperature for six months. Fever was associated with cough and mucoid expectoration for two months along with bilateral symmetrical polyarthritis involving knees, ankles, wrists. However, there was no history of hemoptysis, weight loss, night sweats. He started to experience occasional, colicky abdominal pain with reddish rash distributed over his lower limbs and buttocks seven days prior to his admission. His mother had a history of pulmonary TB six years back and had completed the full course of treatment.

On examination he was pale, febrile with a tender soft to firm lymph node in right upper cervical chain. A maculopapular red rash in both lower limbs and buttocks suggestive of palpable purpura (Figure 1). Chest examination revealed coarse crackles in right mammary area. Tender swollen bilateral symmetrical joints (knees, elbows, and wrists) with diminished range of motion was also found.

Initial investigations revealed—Hemoglobin = 8.3 g/dl, total leucocyte count = 4200 (neutrophil 65%, lymphocyte 33%, monocyte 2%), platelet 2.5 lakhs/cmm³, erythrocyte sedimentation rate = 86 mm first hour, peripheral blood smear—normocytic, normochromic anemia, corrected reticulocyte count = 2.3%, C-reactive protein 7.0 mg/l (<6.0 mg/l). Malarial parasite dual antigen (MPDA), HBsAg, Anti-HCV, HIV (I&II) were negative. Rheumatoid factor, Anti-CCP, Anti-Streptolysin-O were noncontributory, while routine examination of urine, stool did not reveal any abnormality nor did blood C/S. Renal function tests were normal but liver function tests revealed mild transaminitis. Autoimmune markers like ANA (anti-nuclear antibody) PROFILE and profile for collagen vascular diseases were negative along with normal complement assay (C3 and C4). Sputum for culture sensitivity, Gram stain and Z-N stain for acid fast bacilli revealed no growth. Sputum for

CBNAAT came out to be positive for mycobacterium TB, Rifampicin sensitive. Chest X-ray was suggestive of a cavity in middle zone of right lung (Figure 2). Contrast enhanced computed tomography (CT) scan thorax revealed intracavitary lesion with adjacent tree in bud infiltrates noted in the right middle and lower lobe suggestive of secondary TB with endobronchial spread (Figure 3). Ultrasonography of the affected joints showed synovial thickening with minimal effusion in right knee joint. Synovial fluid analysis revealed cell count: 5000 cells/mm³ (lymphocyte predominant) with no crystals, negative cultures and all stains were negative. Cartridge-based nucleic acid amplification test of synovial fluid was negative. Skin biopsy revealed perivascular infiltration of fragmented neutrophils and lymphocytes, features suggestive of leukocytoclastic vasculitis (Figure 4). Direct immunofluorescence (DIF) revealed IgA deposition in the cutaneous vessel wall, suggestive of IgA vasculitis/HSP.

The patient was put on Category 1 anti-tubercular therapy as per Revised National Tuberculosis Control Program (RNTCP) recommendations and the drugs were supplied according to weight-based fixed dose combination. As per his body weight of 45 kg, he was started on three tablets daily of fixed dose combination (FDC) for intensive phase of treatment. Each tablet comprised of Isoniazid (75 mg), Rifampicin (150 mg), Pyrazinamide (400 mg), and Ethambutol (275 mg). After initiation of therapy, his symptoms improved

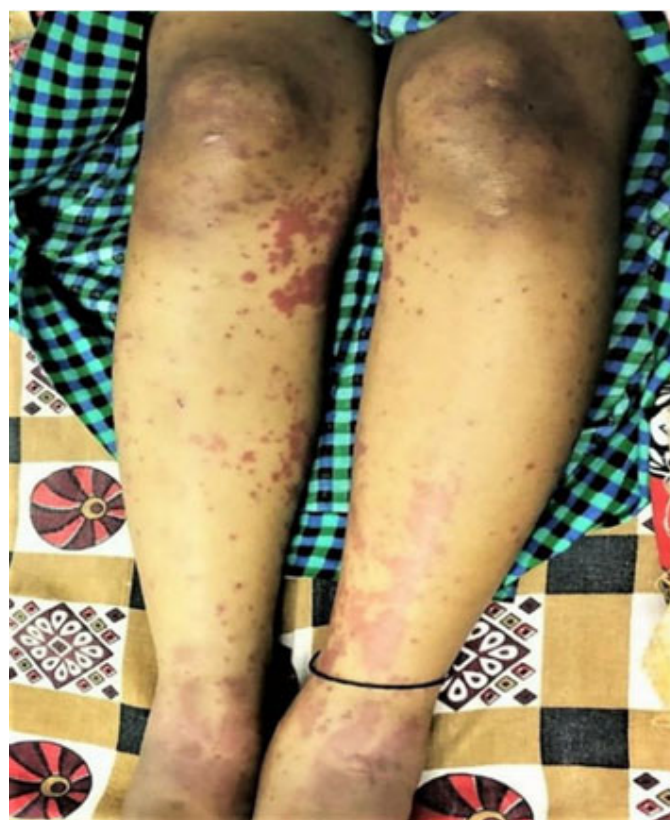

Figure 1: Palpable purpura in lower limbs.

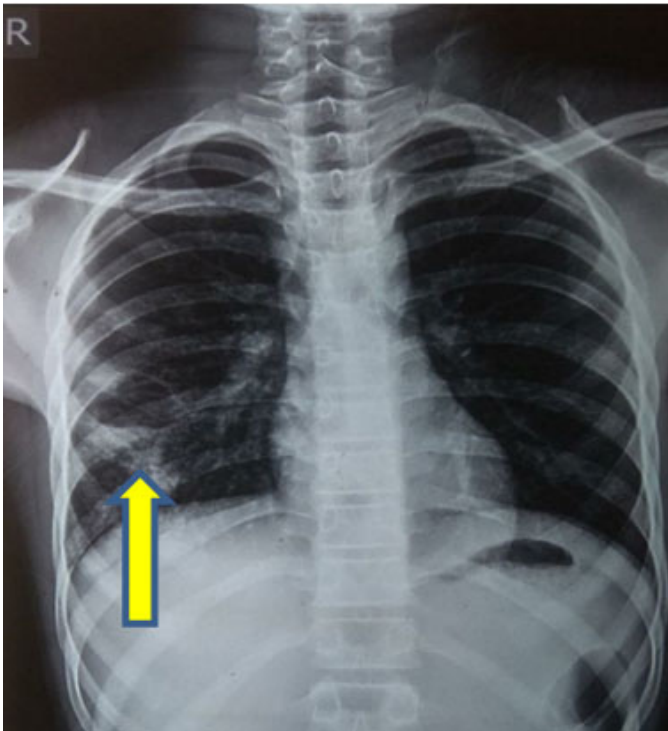


Figure 2: Cavity in middle zone of right lung.

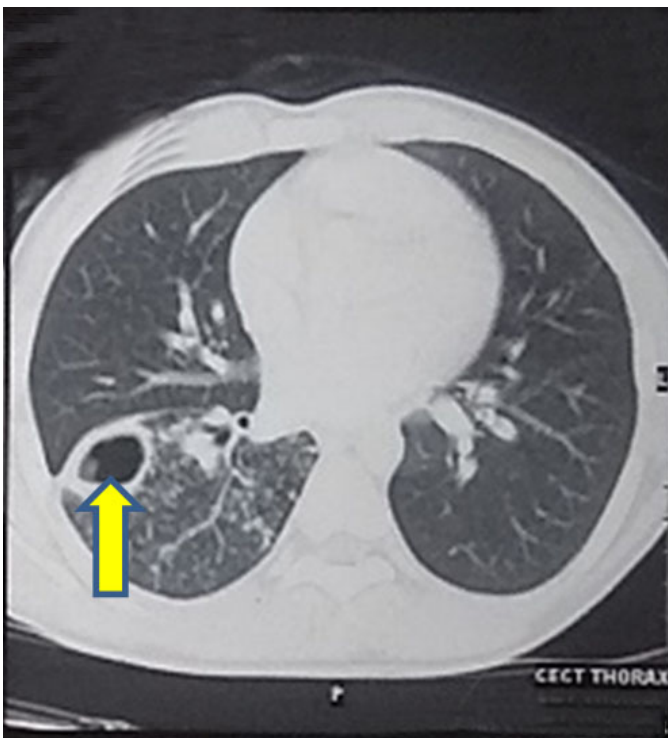


Figure 3: Intracavitary lesion with adjacent tree in bud infiltrates noted in the right middle and lower lobe suggestive of secondary TB with endobronchial spread.

dramatically, the rash resolved spontaneously within two days and the polyarthritis resolved over a few days.

Hence he was diagnosed to be a case of Poncet's disease with IgA vasculitis.

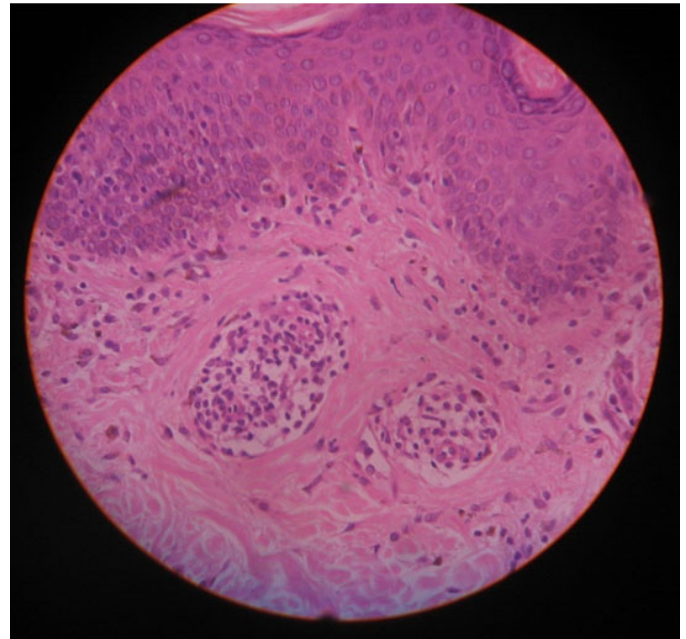


Figure 4: Perivascular infiltration of fragmented neutrophils and lymphocytes, suggestive of leukocytoclastic vasculitis.

DISCUSSION

Tubercular rheumatism/Poncet's disease is a nondestructive oligo/polyarticular joint disease where mycobacteria are not demonstrable in the joint tissue, and is considered as a musculoskeletal manifestation of TB, and associated with extrapulmonary manifestation commonly TB lymphadenitis [5]. The disease is commonly seen in juveniles and young adults predominantly females with symmetrical peripheral polyarthritis involving large joints [6]. Association of Poncet's disease though common with extrapulmonary TB has been associated with active pulmonary TB as reported by Garg et al. [7].

Pathogenesis of Poncet's disease involves a reactive arthritis, mediated by a hypersensitivity reaction against tuberculo-protein probably due to molecular mimicry between mycobacterial antigens and host tissues (mainly heat shock protein, 65) that cross-reacts with human heat shock protein [8].

Diagnostic criteria for Poncet's disease as published by Sharma et al. may be used after excluding other possible explanations of inflammatory arthritis [9].

Poncet's disease is a reactive arthritis in the presence of active TB, although a synovial biopsy is definitive. Poncet's disease and erythema nodosum may be the two sides of the same coin with different expressions of similar immunopathology [10]. However, in our case nonerosive polyarthritis which resolved with initiation of anti-tubercular therapy could not be attributed to any other cause apart from Poncet's disease.

The etiology of HSP may be contributed to many causes like upper respiratory tract infections, subacute bacterial

endocarditis, viral hepatitis, systemic lupus erythematosus, malignancies, TB, acquired immunodeficiency syndrome, hypersensitivity reaction to drugs/immunization, etc. [11]. The leukocytoclastic vasculitis with palpable purpura, typically on the lower extremities and buttocks is highly suggestive of IgA vasculitis. The histopathology suggestive of IgA vasculitis includes destruction of small vessels characterized by a transmural inflammatory infiltrate consisting of neutrophils, endothelial swelling, fibrin deposition, red blood count (RBC) extravasation. However, immune complexes may also play a primary role in the pathogenesis of Henoch–Schönlein vasculitis. Initially, deposition of immunoglobulin or immune complexes in the vessel walls activates alternative complement pathway and leads to subsequent generation of chemotactic factors with neutrophilic infiltration. Phagocytosis of these immune complexes may provoke release of destructive lysosomal enzymes leading to vessel wall injury, thrombosis, and hemorrhage. Deposition of IgA, IgG, IgM along with complement and fibrin was reported in the dermis and mesangium [12]. The cause of the rash in our case could have been due to tuberculosis induced vasculitis/other causes which demanded extensive evaluation but the typical colicky abdominal pain with a maculopapular rash in lower limbs and buttocks, supported by histopathological findings of skin biopsy clinched the diagnosis of IgA vasculitis/HSP. As per literature is concerned, Islek et al. reported an association of pulmonary TB with HSP in pediatric population. However, there are other case reports which have established a link between disseminated tuberculosis and IgA vasculitis [13].

CONCLUSION

Poncet's disease is a nondestructive oligo/polyarthritis usually associated with extrapulmonary tuberculosis. Mechanism is probably a reactive arthritis mediated by hypersensitivity to tuberculo-protein. We hereby report a case of Poncet's disease with pulmonary TB. Association of Poncet's disease with HSP has rarely been reported, but in this case we could establish a diagnosis of Poncet's disease with pulmonary TB and IgA vasculitis/HSP. Hence, clinicians must be cautious while dealing a situation with constellation of such symptoms.

REFERENCES

1. Matheson K, Langley JM, Lang B, Mailman T. Polyarthritis, fever and a rash in a young girl. *Can J Infect Dis Med Microbiol* 2008;19(1):73–4.
2. Dall L, Long L, Stanford J. Poncet's disease: Tuberculous rheumatism. *Rev Infect Dis* 1989;11(1):105–7.
3. Chakraborty PP, Ray S, Selvan C, Bhattacharjee R, Mandal SK. Poncet's disease: An unusual presentation

of tuberculosis in a diabetic lady. *World J Clin Cases* 2015;3(4):385–8.

4. Pugh MT, Southwood TR. Tuberculous rheumatism, Poncet disease: A sterile controversy? [Article in French]. *Rev Rhum Ed Fr* 1993;60(12):855–60.
5. Isaacs AJ, Sturrock RD. Poncet's disease – fact or fiction? A re-appraisal of tuberculous rheumatism. *Tubercle* 1974;55(2):135–42.
6. Bhargava AD, Malviya AN. Tuberculous rheumatism (Poncet's disease) - A case series. *Ind J Tub* 1998;45:215–9.
7. Garg P, Gupta N, Arora M. Monoarticular Poncet disease after pulmonary tuberculosis: A rare case report and review of literature. *Perm J* 2016;20(3):15–199.
8. Holoshitz J, Klajman A, Drucker I, et al. T lymphocytes of rheumatoid arthritis patients show augmented reactivity to a fraction of mycobacteria cross-reactive with cartilage. *Lancet* 1986;2(8502):305–9.
9. Sharma A, Pinto B, Dogra S, et al. A case series and review of Poncet's disease, and the utility of current diagnostic criteria. *Int J Rheum Dis* 2016;19(10):1010–17.
10. Shrivastav A, Mitra B, Pal J. Images in clinical tropical medicine: Reactive arthritis (Poncet's disease) and erythema nodosum accompanying tuberculosis. *Am J Trop Med Hyg* 2009;80(4):501–2.
11. Cream JJ, Gumpel JM, Peachey RD. Schönlein-Henoch purpura in the adult. A study of 77 adults with anaphylactoid or Schönlein-Henoch purpura. *Q J Med* 1970;39(156):461–84.
12. Mackel SE, Jordon RE. Leukocytoclastic vasculitis. A cutaneous expression of immune complex disease. *Arch Dermatol* 1982;118(5):296–301.
13. Han BG, Choi SO, Shin SJ, Kim HY, Jung SH, Lee KH. A case of Henoch-Schönlein purpura in disseminated tuberculosis. *Korean J Intern Med* 1995;10(1):54–9.

Acknowledgments

We thank Dr. Debasish Dey, Assistant Professor, Department of Radiodiagnosis, R.G. Kar Medical College and Hospital, Kolkata for helping us with radiological investigations.

We also thank Dr. Sudip Ghosh, Associate Professor, Department of Dermatology, R.G. Kar Medical College and Hospital, Kolkata for helping us with skin biopsy.

Author Contributions

Uddalak Chakraborty – Conception of the work, Design of the work, Acquisition of data, Analysis of data, Interpretation of data, Drafting the work, Revising the work critically for important intellectual content, Final approval of the version to be published, Agree to be accountable for all aspects of the work in ensuring that questions related to the accuracy or integrity of any part of the work are appropriately investigated and resolved

Tarun Kumar Paria – Acquisition of data, Analysis of data, Interpretation of data, Drafting the work, Final approval of the version to be published, Agree to be accountable for

all aspects of the work in ensuring that questions related to the accuracy or integrity of any part of the work are appropriately investigated and resolved

Atanu Chandra – Conception of the work, Drafting the work, Revising the work critically for important intellectual content, Final approval of the version to be published, Agree to be accountable for all aspects of the work in ensuring that questions related to the accuracy or integrity of any part of the work are appropriately investigated and resolved

Jyotirmoy Pal – Design of the work, Revising the work critically for important intellectual content, Final approval of the version to be published, Agree to be accountable for all aspects of the work in ensuring that questions related to the accuracy or integrity of any part of the work are appropriately investigated and resolved

Guarantor of Submission

I would like to state that this case report is an original manuscript and neither any part nor whole has been published previously in any journal in hard copy/ electronic format nor being considered actively for publication elsewhere. All co-authors have made a subsequent contribution to the design of manuscript and have actively contributed in the diagnosis and management of the case. This manuscript is free from falsification, fabrication, and plagiarism. This is an

original work and I am ready to bear full responsibility and liability regarding this literature. I would like to be the guarantor of submission of this article.

Source of Support

None.

Consent Statement

Written informed consent was obtained from the patient for publication of this article.

Conflict of Interest

Authors declare no conflict of interest.

Data Availability

All relevant data are within the paper and its Supporting Information files.

Copyright

© 2019 Uddalak Chakraborty et al. This article is distributed under the terms of Creative Commons Attribution License which permits unrestricted use, distribution and reproduction in any medium provided the original author(s) and original publisher are properly credited. Please see the copyright policy on the journal website for more information.

Access full text article on
other devices



Access PDF of article on
other devices





INTERNATIONAL JOURNAL OF CASE REPORTS AND IMAGES



VIDEO JOURNAL OF CLINICAL RESEARCH



VIDEO JOURNAL OF BIOMEDICAL SCIENCE



INTERNATIONAL JOURNAL OF HEPATOBILIARY AND PANCREATIC DISEASES



INTERNATIONAL JOURNAL OF BLOOD TRANSFUSION AND IMMUNOHEMATOLOGY



EDORIUM JOURNAL OF OPHTHALMOLOGY



Submit your manuscripts at
www.edoriumjournals.com



EDORIUM JOURNAL OF MEDICINE



EDORIUM JOURNAL OF CARDIOTHORACIC AND VASCULAR SURGERY



JOURNAL OF CASE REPORTS AND IMAGES IN ORTHOPEDICS AND RHEUMATOLOGY



EDORIUM JOURNAL OF PSYCHOLOGY



EDORIUM JOURNAL OF CELL BIOLOGY



JOURNAL OF CASE REPORTS AND IMAGES IN DENTISTRY



EDORIUM JOURNAL OF CANCER



EDORIUM JOURNAL OF PSYCHIATRY



JOURNAL OF CASE REPORTS AND IMAGES IN INFECTIOUS DISEASES



EDORIUM JOURNAL OF ANATOMY AND EMBRYOLOGY



EDORIUM JOURNAL OF SURGERY



JOURNAL OF CASE REPORTS AND IMAGES IN PATHOLOGY



EDORIUM JOURNAL OF ANESTHESIA