

Acute pancreatitis due to pancreatic tail herniation above the left hemidiaphragm

Brian S Lee, Victor Guharoy, Alaa Beydoun, George B Saffouri

CASE REPORT

A 29-year-old female with past medical history of gastroesophageal reflux disease and obesity came to the emergency department with a chief complaint of left upper quadrant abdominal pain. Her symptoms started three days prior after eating a meal. She described the pain as 10/10 intermittent pain that radiated to the back associated with nausea, vomiting, and diaphoresis. She denied alcohol abuse, trauma, or prior abdominal surgeries or procedures. She did not take any medications. Her vital signs were within normal limits. On physical exam, the only notable finding was left upper quadrant tenderness upon palpation.

Laboratory studies showed leukocytosis of 14.8×10^3 cells/mm³ (normal: $3.6-10.2 \times 10^3$ cells/mm³), hematocrit 41.9% (normal: 36.7–47.1%), blood urine nitrogen of 11 mg/dL (normal: 8–21 mg/dL), creatinine of 0.83 mg/dL (normal: 0.57–1.11 mg/dL), and calcium level of 9.3 mg/dL (normal: 8.6–10.2 mg/dL). Total bilirubin and alkaline phosphatase were within normal limits. Alanine aminotransferase and aspartate aminotransferase were slightly elevated at 52 U/L (normal 10–36 U/L) and 37 U/L (normal: 10–30 U/L), respectively. Lipid panel was unremarkable. Lipase was elevated at 265 U/L (lipase laboratory upper limit of normal is 69 U/L). Abdominal

ultrasound showed fatty liver but no evidence of cholelithiasis or common bile duct dilatation. Computed tomography (CT) abdomen and pelvis with intravenous (IV) contrast showed a hiatal hernia with an inflamed pancreatic tail herniated above the left hemidiaphragm (Figures 1–3). Thus, the patient was diagnosed with acute pancreatitis due to pancreatic tail herniation. She was managed conservatively with fluids and analgesia. Her diet was advanced as tolerated (i.e., initially a liquid diet then advanced to a low fat, normal consistency diet which was well tolerated prior to discharge). She improved clinically and was discharged with outpatient follow-up with surgery for hiatal hernia repair.

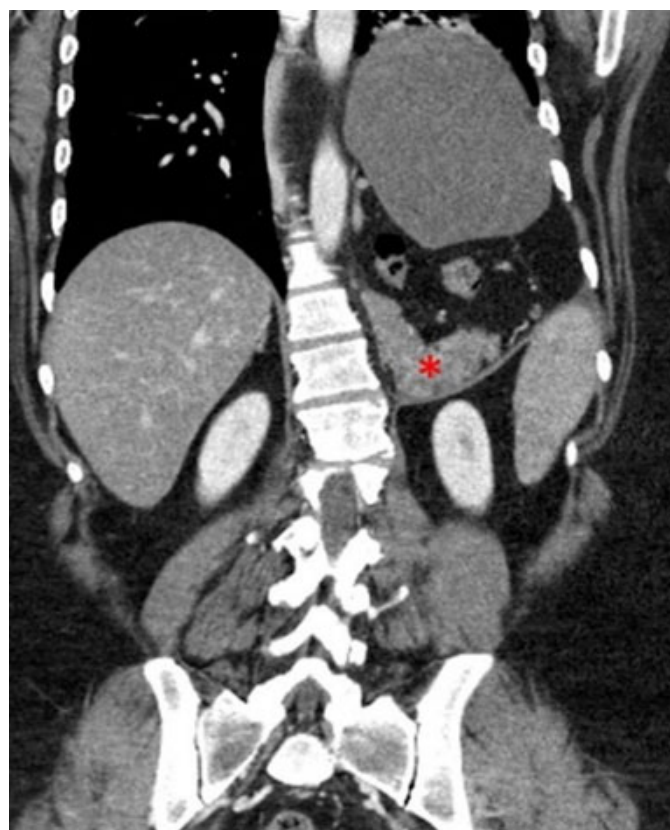


Figure 1: CT abdomen and pelvis with IV contrast coronal view. Herniation of pancreatic tail above the left hemidiaphragm labeled in red asterisk.

Brian S Lee¹, MD, Victor Guharoy², MD, Alaa Beydoun³, MD, George B Saffouri^{1,2}, MD

Affiliations: ¹Department of Internal Medicine, University of California, Riverside School of Medicine, Riverside, CA, USA; ²Division of Gastroenterology, University of California, Riverside School of Medicine, Riverside, CA, USA; ³Department of Radiology, St. Bernardine Medical Center, San Bernardino, CA, USA.

Corresponding Author: Brian S Lee, MD, Department of Internal Medicine, University of California, Riverside School of Medicine, 900 University Avenue, Riverside, CA 92521, USA; Email: brianslee.med@gmail.com

Received: 26 June 2020

Accepted: 09 September 2020

Published: 08 October 2020

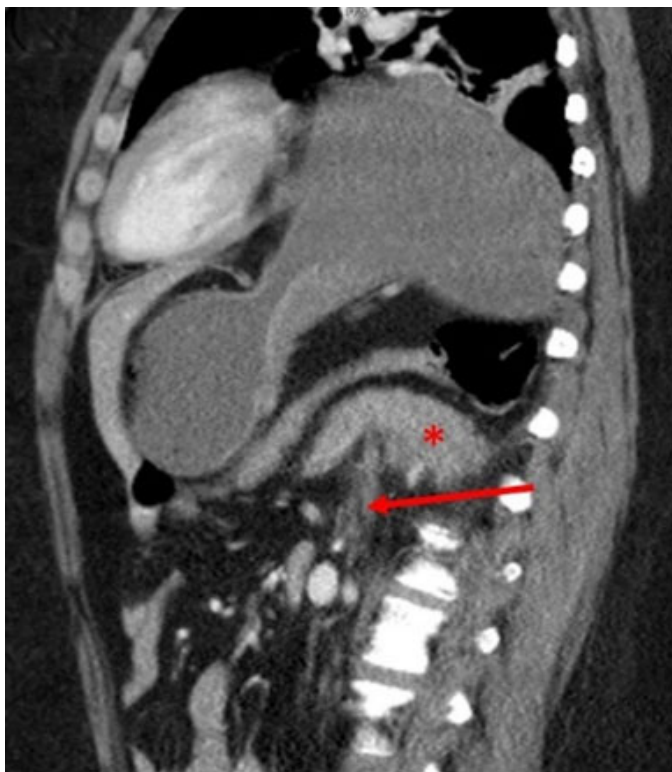

Figure 2: CT abdomen and pelvis with IV contrast sagittal view. Herniation of pancreatic tail above (shown in red asterisk) the left hemidiaphragm (marked in red arrow).

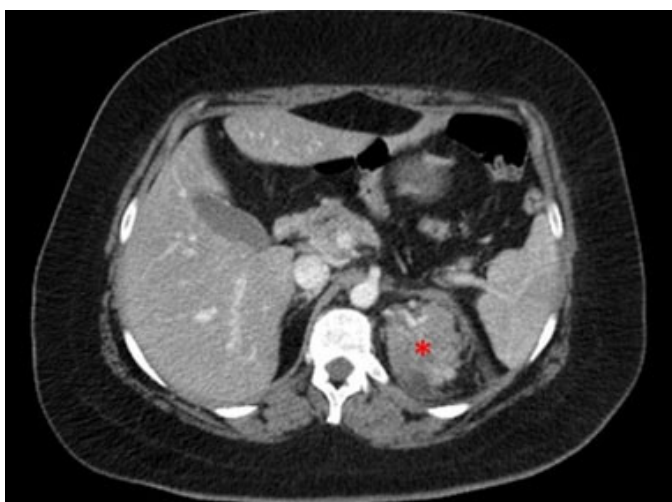


Figure 3: CT abdomen and pelvis with IV contrast axial view. Inflamed pancreatic tail that is herniated above the left hemidiaphragm shown in red asterisk.

DISCUSSION

The pancreas and duodenum are typically held down by the ligament of Treitz. Due to this anatomy, pancreas herniation through the hiatus is rare. It has been proposed that stretching of the transverse mesocolon leads to increased laxity of posterior adhering fascia and enables the pancreas to herniate [1, 2]. Acute pancreatitis

as a complication of this occurrence is even more unusual [3]. Trauma from repetitive transhiatal sliding of the organ, ischemic insults of blood vessels, incarceration of pancreas causing anoxic injury, and pancreatic ductal injuries have been suggested as the mechanisms of this etiology [1, 3–9].

A review of literature reveals that the majority of cases of acute pancreatitis due to a herniated pancreas have been reported in elderly patients with significant comorbidities [3, 4, 10]. More interestingly, the most common finding in this population was herniation of both the body and tail of the pancreas together causing acute pancreatitis [3, 4, 10]. So far, there have been only two cases that reported herniation of only the tail of the pancreas, and both involved a congenital diaphragmatic hernia [8, 9].

Our case is unique in that the patient was young and without many significant comorbidities. Even more unusual was the CT findings showing only the pancreatic tail herniation through the left hemidiaphragm, which caused her acute pancreatitis. To our knowledge, this is the first case of pancreatic tail herniation causing acute pancreatitis in a young female adult. Moreover, pancreatic tail herniation was not associated with a congenital diaphragmatic hernia. Although tail-only herniation likely occurs in the same proposed mechanism as discussed previously, it is unclear at this time why these are less commonly reported in the literature. It is conceivable that tail-only herniation is less likely to manifest in significant clinical symptoms compared to body and tail herniation because it involves a smaller portion of the pancreas. More research is needed to understand why certain parts of the pancreas becomes herniated and how this affects clinical presentations.

CONCLUSION

Acute pancreatitis as a complication of pancreatic tail herniation through the hiatus is rare. This case emphasizes the importance of generating a broad differential and the value of cross-sectional imaging in evaluating acute pancreatitis without clear risk factors.

Keywords: Abdominal pain, Herniation, Pancreatitis

How to cite this article

Lee BS, Guharoy V, Beydoun A, Saffouri GB. Acute pancreatitis due to pancreatic tail herniation above the left hemidiaphragm. *J Case Rep Images Med* 2020;6:100056Z09BL2020.

Article ID: 100056Z09BL2020

doi: 10.5348/100056Z09BL2020CI

REFERENCES

1. Chevallier P, Peten E, Pellegrino C, Souci J, Motamedi JP, Padovani B. Hiatal hernia with pancreatic volvulus: A rare cause of acute pancreatitis. *AJR Am J Roentgenol* 2001;177(2):373-4.
2. Patel S, Shahzad G, Jawairia M, Subramani K, Viswanathan P, Mustacchia P. Hiatus hernia: A rare cause of acute pancreatitis. *Case Rep Med* 2016;2016:2531925.
3. Wang J, Thaker AM, Noor El-Nachef W, Watson RR. Transhiatal herniation of the pancreas: A rare cause of acute pancreatitis. *ACG Case Rep J* 2017;4:e66.
4. Zackria R, Popa A. Transhiatal herniation as the cause of acute pancreatitis after toupet fundoplication. *ACG Case Rep J* 2019;6(8):e00156.
5. Kafka NJ, Leitman IM, Tromba J. Acute pancreatitis secondary to incarcerated paraesophageal hernia. *Surgery* 1994;115(5):653-5.
6. Lu LX, Payne M, Theobald CN. Education and imaging. *Gastroenterology: Diaphragmatic herniation and pancreatitis. J Gastroenterol Hepatol* 2015;30(4):653.
7. Rozas MG, González MM. A rare complication of hiatal hernia. *Gastroenterology* 2010;139(6):e1-2.
8. Cuschieri RJ, Wilson WA. Incarcerated Bochdalek hernia presenting as acute pancreatitis. *Br J Surg* 1981;68(9):669.
9. Oliver MJ, Wilson AR, Kapila L. Acute pancreatitis and gastric volvulus occurring in a congenital diaphragmatic hernia. *J Pediatr Surg* 1990;25(12):1240-1.
10. Do D, Mudroch S, Chen P, Prakash R, Krishnamurthy P. A rare case of pancreatitis from pancreatic herniation. *J Med Cases* 2018;9(5):154-6.

Author Contributions

Brian S Lee – Conception of the work, Design of the work, Acquisition of data, Analysis of data, Interpretation of data, Drafting the work, Revising the work critically for important intellectual content, Final approval of the version to be published, Agree to be accountable for all aspects of the work in ensuring that questions related to the accuracy or integrity of any part of the work are appropriately investigated and resolved

Victor Guharoy – Conception of the work, Design of the work, Acquisition of data, Analysis of data, Interpretation of data, Drafting the work, Revising the work critically for important intellectual content, Final approval of the

version to be published, Agree to be accountable for all aspects of the work in ensuring that questions related to the accuracy or integrity of any part of the work are appropriately investigated and resolved

Alaa Beydoun – Conception of the work, Design of the work, Acquisition of data, Analysis of data, Interpretation of data, Drafting the work, Revising the work critically for important intellectual content, Final approval of the version to be published, Agree to be accountable for all aspects of the work in ensuring that questions related to the accuracy or integrity of any part of the work are appropriately investigated and resolved

George B Saffouri – Conception of the work, Design of the work, Acquisition of data, Analysis of data, Interpretation of data, Drafting the work, Revising the work critically for important intellectual content, Final approval of the version to be published, Agree to be accountable for all aspects of the work in ensuring that questions related to the accuracy or integrity of any part of the work are appropriately investigated and resolved

Guarantor of Submission

Dr. George B Saffouri, MD is the guarantor of the submission. Division of Gastroenterology, University of California, Riverside School of Medicine, 900 University Avenue, Riverside, CA 92521, USA. Email: gbsaffouri@gmail.com

Source of Support

None.

Consent Statement

Written informed consent was obtained from the patient for publication of this article.

Conflict of Interest

Authors declare no conflict of interest.

Data Availability

All relevant data are within the paper and its Supporting Information files.

Copyright

© 2020 Brian S Lee et al. This article is distributed under the terms of Creative Commons Attribution License which permits unrestricted use, distribution and reproduction in any medium provided the original author(s) and original publisher are properly credited. Please see the copyright policy on the journal website for more information.

Access full text article on
other devices



Access PDF of article on
other devices





INTERNATIONAL JOURNAL OF
CASE REPORTS AND IMAGES



VIDEO JOURNAL OF
CLINICAL RESEARCH



VIDEO JOURNAL OF
BIOMEDICAL SCIENCE



INTERNATIONAL JOURNAL OF
HEPATOBIILIARY AND
PANCREATIC DISEASES



INTERNATIONAL JOURNAL OF
BLOOD TRANSFUSION AND
IMMUNOHEMATOLOGY



EDORIUM JOURNAL OF
OPHTHALMOLOGY



Submit your manuscripts at
www.edoriumjournals.com



EDORIUM JOURNAL OF
MEDICINE



EDORIUM JOURNAL OF
CARDIOTHORACIC AND
VASCULAR SURGERY



JOURNAL OF CASE REPORTS
AND IMAGES IN ORTHOPEDICS
AND RHEUMATOLOGY



EDORIUM JOURNAL OF
PSYCHOLOGY



EDORIUM JOURNAL OF
CELL BIOLOGY



JOURNAL OF CASE REPORTS AND IMAGES IN
DENTISTRY



EDORIUM JOURNAL OF
CANCER



EDORIUM JOURNAL OF
PSYCHIATRY



JOURNAL OF CASE REPORTS AND
IMAGES IN INFECTIOUS DISEASES



EDORIUM JOURNAL OF
ANATOMY AND EMBRYOLOGY



EDORIUM JOURNAL OF
SURGERY



JOURNAL OF CASE REPORTS
AND IMAGES IN PATHOLOGY



EDORIUM JOURNAL OF
ANESTHESIA